



VCU

Virginia Commonwealth University
VCU Scholars Compass

Theses and Dissertations

Graduate School

2010

Use of Cone Beam Computed Tomography in the Determination of Mental Foramen Location in Relation to Mandibular 1st and 2nd Premolars

Sanjay Bhagchandani
Virginia Commonwealth University

Follow this and additional works at: <https://scholarscompass.vcu.edu/etd>



Part of the [Endodontics and Endodontology Commons](#)

© The Author

Downloaded from

<https://scholarscompass.vcu.edu/etd/2165>

This Thesis is brought to you for free and open access by the Graduate School at VCU Scholars Compass. It has been accepted for inclusion in Theses and Dissertations by an authorized administrator of VCU Scholars Compass. For more information, please contact libcompass@vcu.edu.

Use of Cone Beam Computed Tomography in the Determination of Mental
Foramen Location in Relation to Mandibular 1st and 2nd Premolars

A thesis submitted in partial fulfillment of the requirements for the degree of Master of
Science in Dentistry at Virginia Commonwealth University.

by

Sanjay Bhagchandani
DMD, Tufts University School of Dental Medicine
BS, Duke University

Program Director: Karan J. Replogle DDS, MS,
Chair and Postgraduate Program Director, Endodontics

Virginia Commonwealth University
Richmond, Virginia
May, 2010

Acknowledgment

The author wishes to thank several people. I would like to thank my wife, Trisha, for her love, support and patience. I would like to thank my parents for their unending love and support. I would also like to thank Drs. Replogle, Black, Strauss, and Best for their help and direction with this project.

Table of Contents

List of Tables	iv
List of Figures	v
Abstract	vi
Introduction	1
Methods and Materials	5
Results.....	9
Conclusion.....	18
Vita.....	27

List of Tables

Table	Page
1. Overall Location of the Mental Foramen.....	9
2. Horizontal and Vertical Position.....	10
3. Screening for Relationships, p-values.....	11
4. Relationship between Distance and Position.....	15
5. Correlation of Left Sided Measurements and Right Sided Measurements.....	17

List of Figures

Figure	Page
1. Marking of the Apex of the Mandibular First Premolar (1a) and the Mental Foramen (1b) for Measurement.....	6
2. Measurement from Base of Foramen to Inferior Border of Mandible.....	7
3. Mesio-distal Position of Mental Foramen.....	7
4. Mesio-distal Position of Mental Foramen Percentages.....	10
5. Relationships between Distance and Sex, Age, and Side of Mandible.....	12
6. Relationships between Horizontal and Vertical Positions and Sex, Age, and Side of Mandible.....	14
7. Relationship between Distance from Apices to Foramen and Horizontal and Vertical Position of the Foramen.....	16

Abstract

USE OF CONE BEAM COMPUTED TOMOGRAPHY IN THE DETERMINATION OF MENTAL FORAMEN LOCATION IN RELATION TO MANDIBULAR 1ST AND 2ND PREMOLARS

By Sanjay P. Bhagchandani DMD, BS

A thesis submitted in partial fulfillment of the requirements for the degree of Master of Science in Dentistry at Virginia Commonwealth University.

Virginia Commonwealth University, 2010

Program Director: Karan J. Replogle DDS, MS,
Chair and Postgraduate Program Director, Endodontics

The purpose of this study was to use existing Cone Beam Computer Tomography images to determine the vertical and horizontal location of the mental foramen in relation to the mandibular first and second premolars, as well as the distance in millimeters from the apex of each. The distance from the inferior border of the foramen to the inferior border of the mandible was also recorded.

The average distance from the apices of the mandibular first and second premolars to the mental foramen was 7.43mm (SD= 1.97) and 5.30mm (SD=1.65) respectively. The foramen was located 11.44mm (SD=1.49) from the inferior border of the mandible. The foramen was in line with the apex of the mandibular second premolar 41% of the time. The mental foramen was further away from the inferior border of the mandible in males and older patients. Mental foramina seemed to be positioned more apically and distally in older patients.

Introduction

Knowledge and location of neurovascular bundles and sinus structures in the mandible and maxilla is essential in the proper placement of implants, successful osteotomies, and complication free apicoectomies. Without proper identification of anatomical landmarks, surgical complications can include, but are not limited to, sinus floor perforation and neural trauma.

Neural trauma is seen mostly in the mandible and can be attributed to damage to the inferior alveolar nerve or the mental nerve (31). Without knowledge of the location of the neurovascular bundle, surgical procedures can lead to bruising, transportation, or complete dissection. Any of these complications are known to cause dysphasia, paresthesia, or anesthesia. Advanced planning and three-dimensional knowledge of the surgical site anatomy limits unnecessary sequelae. In addition to locating the foramen to avoid surgical complications, the location of the foramen should also be determined so that it is not confused for a periapical lesion approximating the apex of either mandibular premolar.

The mental nerve is the general somatic afferent nerve that is the terminal branch of the posterior trunk of the inferior alveolar nerve, which is a branch of the mandibular division of the trigeminal nerve. The nerve is accompanied by the mental artery, a branch of the inferior alveolar artery. The mental foramen is the anatomical landmark that

represents the exit for the mental nerve from the inferior alveolar canal (1,2). After the mental nerve and artery pass through the foramen, they supply sensory innervation and circulation to the areas of the skin of the lower lip, chin, and the alveolar mucosa and gingiva anterior to the second premolar.

Determination of the mental nerve's position is essential in avoiding damage to the nerve during various surgical procedures. The mental foramen, usually located on a radiograph as a radiolucent circle, can be confused with a periapical lesion approximating the apex of either mandibular premolar. Much effort has been given to locating the mental foramen. Many authors have dedicated themselves to describing the size, location, and orientation of the mental foramen utilizing either dissected mandibles or radiographs. The diameter of the foramen has been found to range from 2.47 - 7.3mm (3-6). Horizontal location of the foramen, in relation to the apices of the mandibular premolars, varies among researchers. Some studies show that the majority of foramina are apical to the second premolar (7-11), while others demonstrate that the foramen is most likely to be found mesial to the apex of the second premolar (5,12,13). Vertical position of the foramen, in relation to the root apices of the mandibular premolars, is also of interest during surgical procedures. The foramen can exist either above or below the apex of the second premolar (12,14). Once the canal exits from the foramen, the orientation of the mental nerve has been found to be mostly in the posterior or posterior-superior direction (6,15,16).

The mental foramen has no distinct anatomical landmarks and is not easily

visualized or palpated. Due to difficulty in locating the mental foramen, the data from these previous studies have been used to help plan ahead for various surgical procedures. The data have been obtained by either direct dissection of human mandibles or by measuring radiographs. While radiographs give the practitioner an idea of the location of the mental foramen, they do not give a three-dimensional image of the orientation of the neurovascular bundle, nor do radiographs help differentiate the mental foramen from an apical radiolucency associated with pulpal pathosis of the mandibular premolars.

The ideal image for the planning of surgeries in the area of the mental foramen would be an image that is three dimensional in nature and has a very high spatial resolution at low exposures. These attributes can be achieved with Cone Beam Computed Tomography (CBCT), which not only make it an ideal form of imaging, but also allow for a precise understanding of the relationship between structures in an anatomically complex area (17,18).

The use of panoramic radiographs has demonstrated the ability to clearly visualize the mental foramen only 49-64% of the time (3). Likewise, periapical radiographic location of mental foramina proved to be accurate 46.8-75% of the time (6,12). These studies have shown that the use of periapical or panoramic radiographs can be limited due to focal plane shape, projection geometry, vertical over or under angulation, horizontal angulation, and faulty patient position (19-27). Due to some of these limitations and the progression of technology, CBCT has gained popularity and acceptance in all fields of dentistry (28). CBCT has proven to have an error of less than 0.6% when measuring mandibular anatomy (29). It also has proven to be accurate when measuring

simulated bone defects in acrylic blocks with a mean width accuracy of -0.01mm and mean height difference of -0.03mm (30).

Due to the importance of the location of the mental foramen when planning for dental surgical procedures (31), the lack of agreement on the location, size and orientation, and the advances in CBCT, a more updated study of the foramen was initiated. The purpose of this study was to use existing CBCT images to determine the vertical and horizontal location of the mental foramen in relation to the mandibular first and second premolars, as well as the distance in millimeters from the apex of each. The distance from the inferior border of the foramen to the inferior border of the mandible was also recorded.

Methods and Materials

Data from CBCT examinations of 29 of a total of 93 patients who had undergone dental implant, maxillofacial surgical, surgical endodontic, or orthodontic treatment planning from August 2008 to December 2009 were retrospectively analyzed. Patients at Virginia Commonwealth University sign an informed consent allowing the use of radiographs and other data for use in retrospective studies. Excluded were seven patients being evaluated after mandibular surgery, fifty-one edentulous, and six patients with severe craniofacial abnormalities such as Pierre Robin syndrome and Treacher Collins syndrome.

A CBCT unit, NewTom VG (QR SRL, an AFP Imaging Co., Elmsford, NY USA), with an amorphous silicon flat-panel detector was used. The exposure volume was set at 16 cm in diameter and 14 cm in height. The voxel size was 0.3 X 0.3 X 0.3 mm. The scan was set at 110 kV and 1-20 mA (pulsed mode), as recommended by the manufacturer. Patients were positioned with the occlusal plane set parallel to the floor base using a head strap and a chinrest. The DICOM files of the axial images were saved to a portable hard disk (HD).

Volumetric data from the 29 CBCT examinations was reconstructed to produce 2-dimensional images in serial planes as well as 3-dimensional images of the entire mandible. A desktop computer (Dell Inc., Round Rock, TX USA) using NNT software

(QR SRL, an AFP Imaging Co., Elmsford, NY USA) was used to reconstruct the images. Once images were reconstructed the location of the mental foramina became clear in the body of the mandible. Apices of mandibular premolars also became evident through a series of cross-sectional cuts from the coronal to apical portions of the premolars.

Six measurements relating to the position of the mental foramen were taken on each side of the mandible using the NNT software. Two of the measurements represent the distance, in millimeters, from the apices of each mandibular premolar to the mental foramen. The measurements were true 3-dimensional measurements that represented the shortest straight-line distance from tooth to foramen. In other words, the measurement represented the hypotenuse represented by the angle made up of the height from apex to foramen and depth through the mandible from apex to foramen (Fig. 1a & 1b). A third measurement was the distance from the base of the foramen to the inferior border of the mandible (Fig. 2).

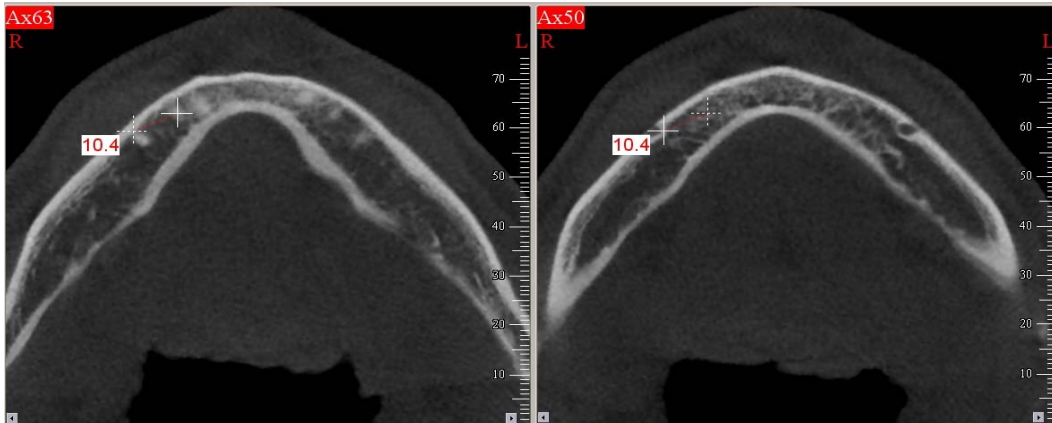


Fig. 1a and 1b: Marking of the apex of the mandibular first premolar (1a) and the mental foramen (1b) for measurement

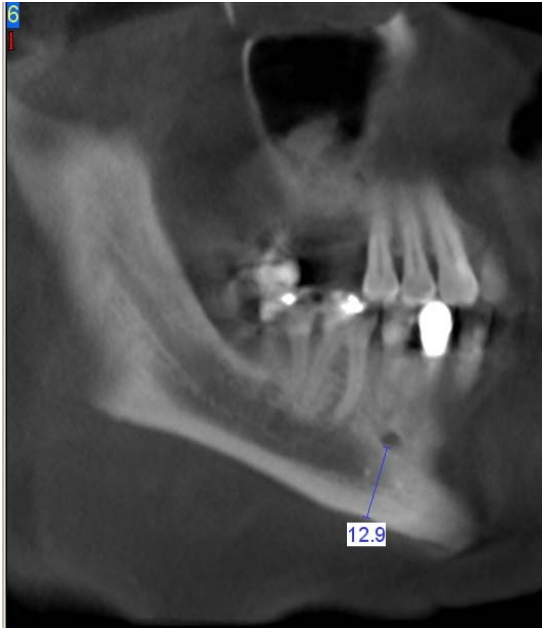


Fig. 2: Measurement from base of foramen to inferior border of mandible

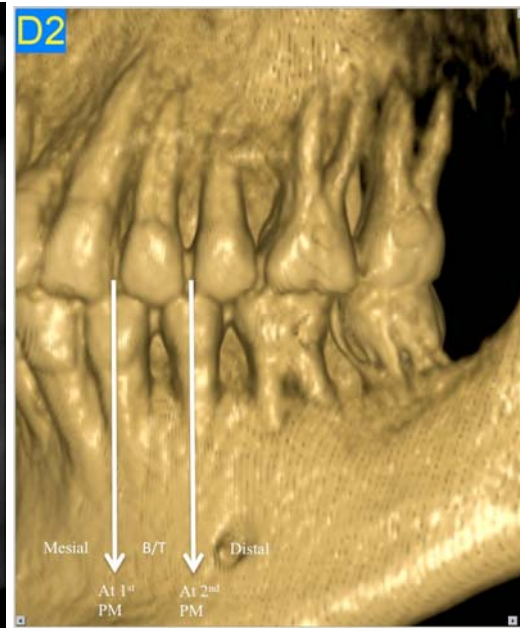


Fig. 3: Mesio-distal position of mental foramen

The three remaining measurements were qualitative in nature. The coronal-apical position of the foramen in relationship to the premolar apices was recorded, as was the mesio-distal position of the foramen in relation to the roots of the mandibular premolars. Straight lines were drawn through the crowns of the mandibular premolars and the mesio-distal relationship was defined as either mesial to first premolar, at the apex of the first premolar, between first and second premolar, at the apex of the second premolar, or distal to the second premolar (Fig. 3).

In order to determine if there were systematic differences between males and females, the left and right side, or age related trends, these covariates were used as potential predictors in multivariable models. For the quantitative measurements (the three distances), a repeated-measures multi-way ANOVA analysis was used. For the

qualitative measurements (the three position variables), a repeated-measures multi-way logistic regression analysis was used. When screening for potential relationships an alpha < 0.2 criterion was used.

Results

A total of n = 29 patients (58 foramina) were assessed by CBCT, with an approximately equal number of females (n = 15) and males (n = 14). The average age was 46.5 years (SD = 15.9, range = 19 to 76). Overall, the location of the mental foramen in millimeters is shown in Table 1. Horizontal location can be visualized in Figure 4.

Table 1: Overall Location of the Mental Foramen

Characteristic	Mean	Std Dev	Min	Max
Distance to (mm):				
• 1st premolar	7.43	1.97	3.5	12.5
• 2nd premolar	5.30	1.65	2.1	10.1
• Inferior border	11.44	1.49	8.2	13.8
	n	%		
Horizontal position				
• Distal to 2nd premolar	9	16		
• At 2nd premolar	24	41		
• Between 1st & 2nd	22	38		
• At 1st premolar	3	5		
• Mesial to 1st premolar	0	0		
Vertical position relative to 1st premolar				
• Coronal	10	17		
• Apical	48	83		
Vertical position relative to 2nd premolar				
• Coronal	10	17		
• Apical	48	83		

The relation between horizontal and vertical position is shown in Table 2.

Vertically, the location is apical to both the first and second premolar root tip (45 out of

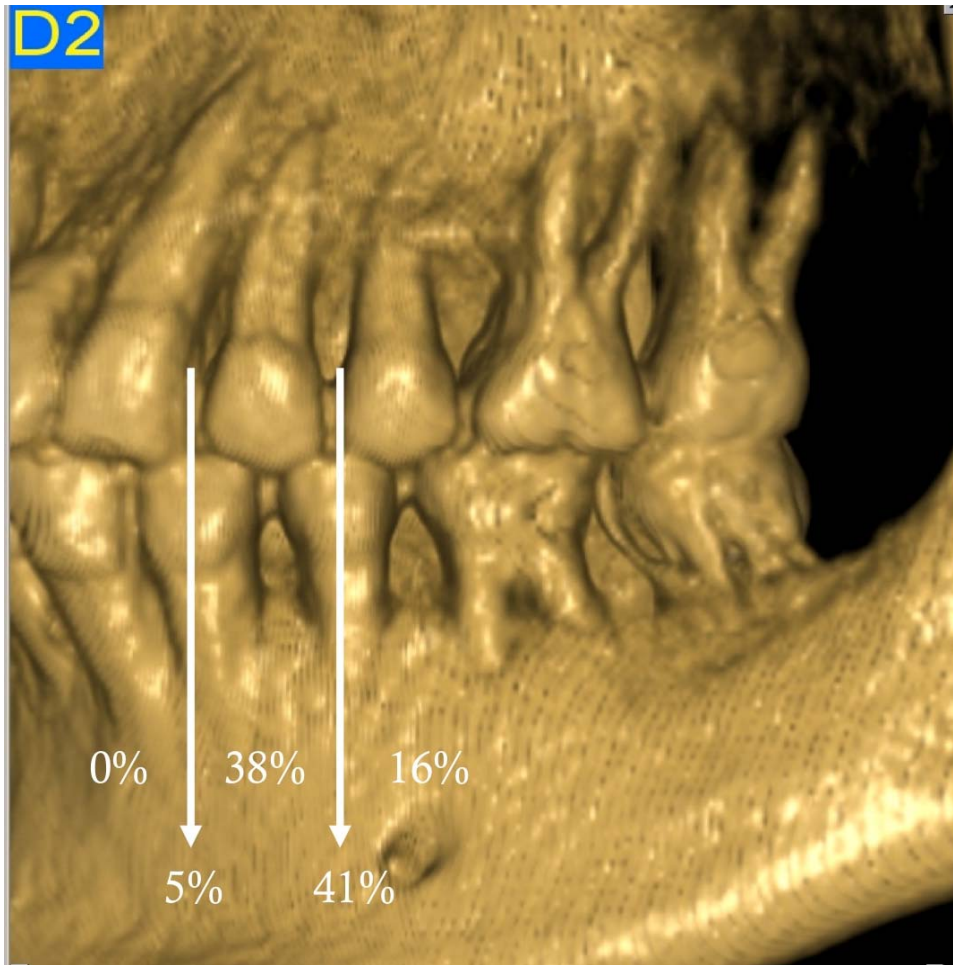
58) and is either at the 2nd premolar or between the 1st and 2nd (22+24 out of 58).

Table 2: Horizontal and Vertical Position

Vertical Position (1 st , 2 nd)	Horizontal Position					Total
	Distal to 2 nd premolar	at 2 nd premolar	between 1 st & 2 nd	at 1 st premolar	Mesial to 1 st premolar	
C,C	1	3	3	0	0	7
C,A	0	2	1	0	0	3
A,C	1	0	2	0	0	3
A,A	7	19	16	3	0	45
Total	9	24	22	3	0	58

(CC=coronal to apices of both 1st and 2nd premolars, CA=coronal to 1st and apical to 2nd, AC=apical to 1st and coronal to 2nd, AA= apical to apices of both 1st and 2nd premolars)

Fig. 4: Mesio-distal Position of Mental Foramen Percentages



In order to determine if there are systematic differences between males and females, the left and right side, or age related trends, these covariates were used as potential predictors in multivariable models. For the continuous outcomes in Table 1 (the three distances), a repeated-measures multi-way ANOVA analysis was used. For the nominal outcomes in Table 1 (the three position variables), a repeated-measures multi-way logistic regression analysis was used. When screening for potential relationships between variables in this study, an $\alpha < 0.2$ criterion was used.

Table 3 shows that there are sex-related differences on the distance to the 1st premolar ($p > 0.18$), but that there is no evidence for differences in the distance to the 2nd premolar ($p > 0.26$). There does seem to be clear indication of sex and age related differences in the distance to the inferior border ($p < .003$). There is evidence for horizontal position differences related to sex ($p = 0.08$), but not for age, or side ($p > 0.2$), but there is some evidence for right/left differences on the vertical position relative to the 1st premolar ($p = 0.16$) but not the 2nd premolar ($p = 0.5$). Significant p-values are in bold in Table 3.

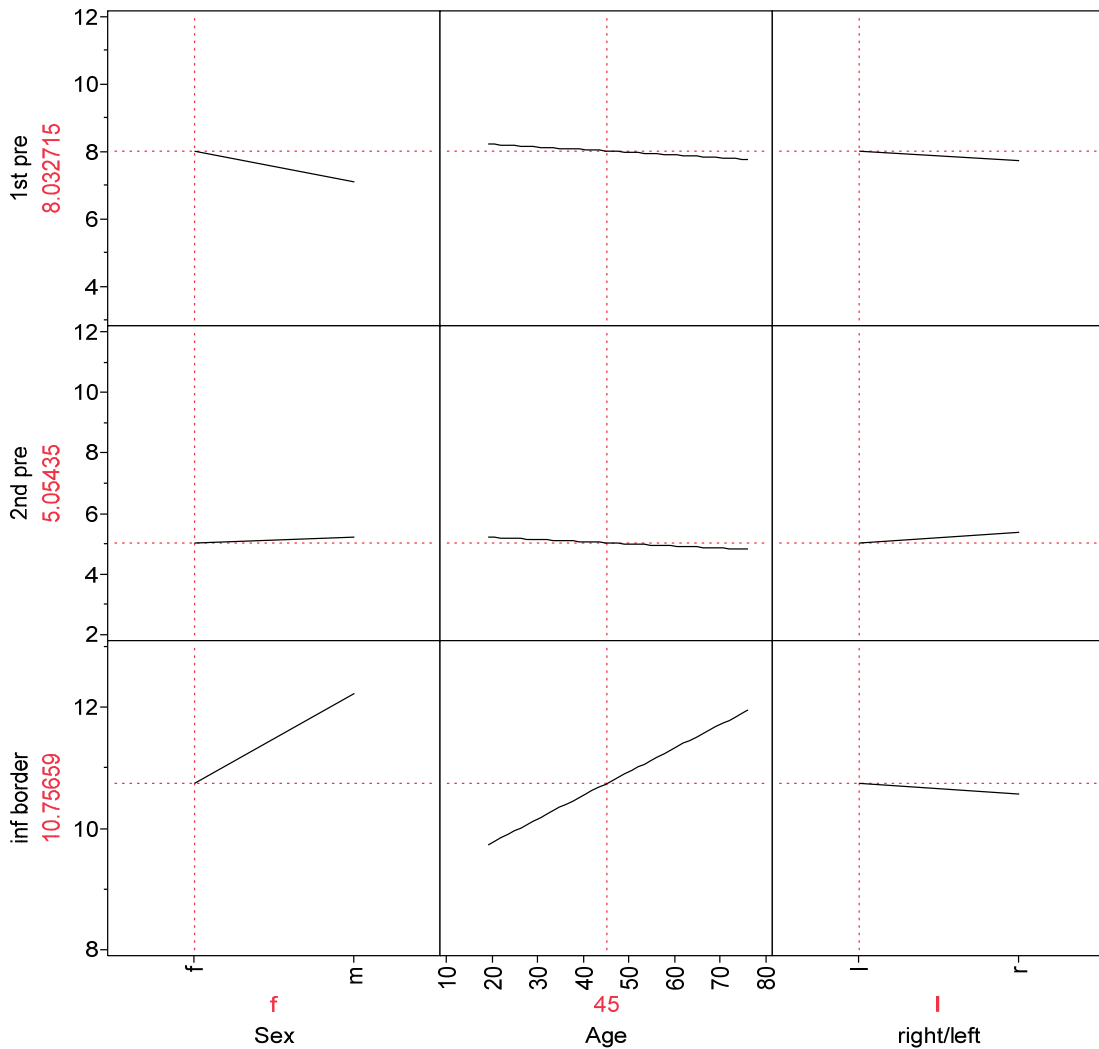
Table 3: Screening for relationships, p-values

Predictor	Distance to			Position		
	1st premolar	2nd premolar	inferior border	Hori- zontal	Vertical, 1st	Vertical, 2nd
Sex	0.1719	0.7466	0.0004	0.0823	0.9098	0.9029
Age	0.7081	0.6896	0.0027	0.2244	0.2692	0.7568
Right/Left	0.3773	0.2680	0.4550	0.7026	0.1550	0.4853

The relationships between each of the predictors and the distance measures are shown in Figure 5. For the distance to the first premolar, females have an average distance of 7.87 (SE = 0.457, 95% CI = 6.93 to 8.81) while males have an average

distance of 6.95 (SE = 0.473, 95% CI = 5.98 to 7.92). Distance differences for the 2nd premolar were not found to be significant. For the inferior border measurement, the distance increases 0.0885 (SE = 0.0118) for each year with females having an average distance of 10.73 (SE = 0.257, 95% CI = 10.20 to 11.26) while males have an average distance of 12.21 (SE = 0.266, 95% CI = 11.66 to 12.75).

Fig. 5: Trend Differences between Age, Males and Females, Side of Mandible
 (X axis: Variables, Y axis: Average Distance in Millimeters for 45 Year Old Female on Left Side of Mandible)



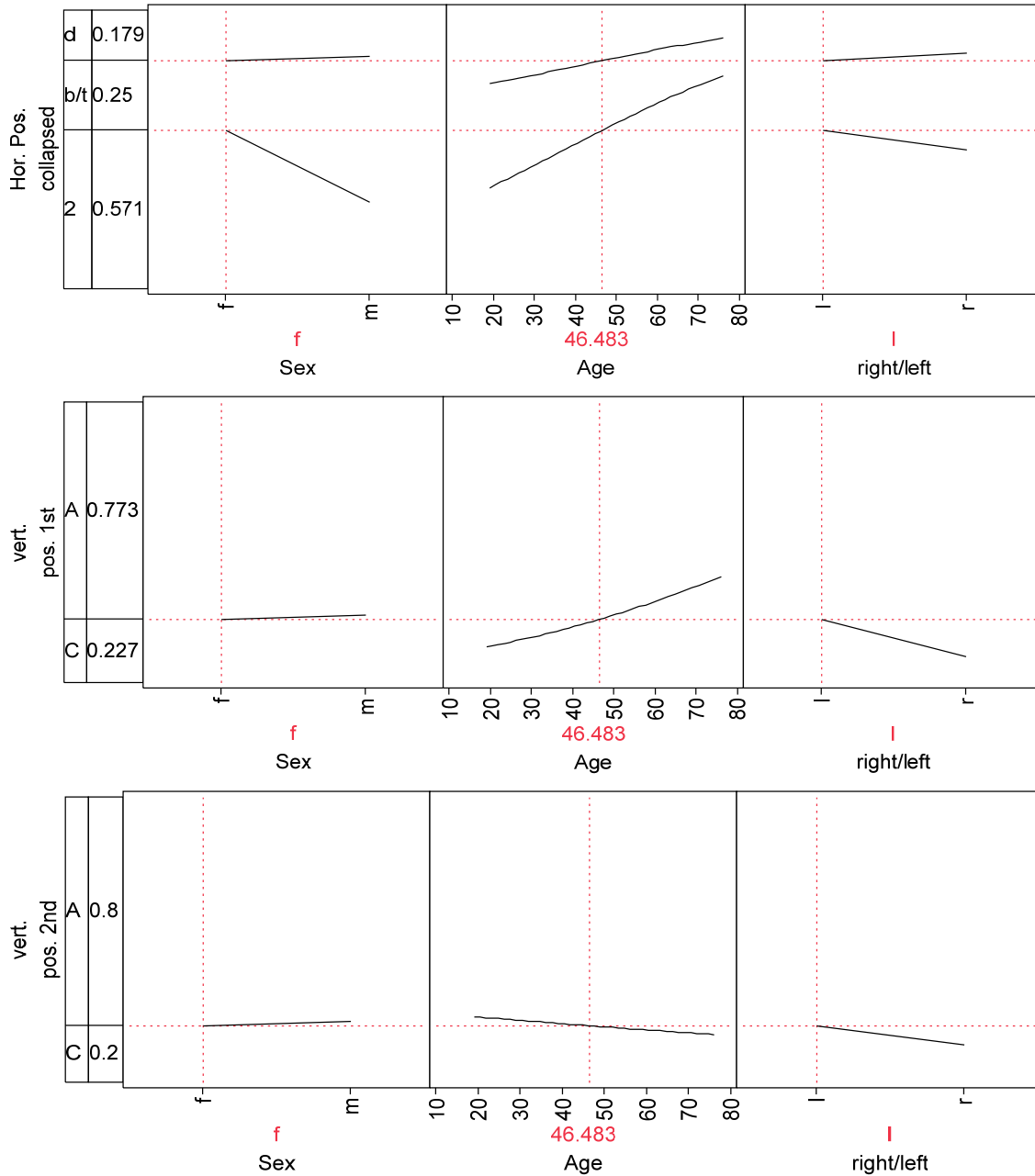
The relationship between horizontal and vertical positions, gender, age, and side of the mandible are shown in Figure 6. To show the relationships to horizontal position, the “at 1st premolar” category (n = 3) was collapsed into the next category, “between 1st and 2nd”. The vertical scale in Figure 5 is the proportion in each outcome category where “d” = distal to 2nd premolar, “b/t” = between 1st and 2nd premolars, and “2” = in line with the 2nd premolar. The lines show how these proportions change depending upon the predictor. In the top-most figure, the probability of the position being in “d”, “b/t”, and “2” is shown, respectively. The proportion of cases that were in the “d” location is 0.179 for Sex=f, Age = 46.5 (the mean), and Right/Left=l. As may be seen, this proportion is essentially unchanged for Sex=m (the line is flat), but increases slightly for older cases (the line increases), and is essentially unchanged for the right side. For these same levels of the predictors, the proportion “b/t” is 0.25 and the separation between the lines (and the downward trend) show that this proportion is higher for males, decreases with age (the separation between the lines is less), and increases slightly for the right side. For these same levels of the predictors, the proportion “2” is 0.571 for females and decreases for males. The proportion “2” increases substantially with age and is nearly unchanged for the right side.

The middle pane of Figure 6 shows the proportion of foramen located apical to the apex of the 1st premolar (“A”) or coronal to the apex of the 1st premolar (“C”). For females of age 45 on the left side, the proportion “C” is 0.227. There is no apparent difference for males but the proportion increased with age and decreased on the right side

(although not significantly). The bottom pane of Figure 6 shows the proportion “A” or “C” relative to the 2nd premolar. The flat lines indicate that these proportions are essentially unchanged by sex, age, or side.

Fig. 6: Relationships between Horizontal and Vertical Positions and Sex, Age, and Side of Mandible

(d = distal to 2nd premolar, b/t = between 1st and 2nd premolars, 2 = at 2nd premolar, A = apical to apex, C = coronal to apex)



Additionally, the differences were tested between the mean distances depending upon the three position measures. A multi-way ANOVA indicated that horizontal position is related to the 1st premolar distance ($p = 0.0020$) and to the 2nd premolar distance ($p = 0.0008$) but not the distance to the inferior border ($p > 0.8$) (see Table 4). The lower panel of Table 4 shows the mean distances depending upon horizontal position.

There also appears to be differences in the 2nd premolar distance depending upon the vertical position relative to the 1st premolar ($p < 0.03$) and the 2nd premolar ($p < 0.1$). The distance to the 2nd premolar is 4.67mm (SE = 0.49) for those coronal to the apex of the 1st premolar and 5.98mm (SE = 0.37) for those apical to the apex of the 1st premolar. The distance to the 2nd premolar is 5.83mm (SE = 0.49) for those coronal to the apex of the 2nd premolar and 4.83mm (SE = 0.38) for those apical to the apex of the 2nd premolar.

Table 4: Relationship between Distance and Position
(P-values Bolded are Significant)

Position	Distance to		
	1 st premolar	2 nd premolar	inferior border
Horizontal	0.0020	0.0008	0.8217
Vert. 1st	0.4731	0.0293	0.1610
Vert. 2nd	0.7057	0.0957	0.9516

Estimated Distance Depending upon Horizontal Position (Distance in mm)

Horizontal Position	Distance to 1st premolar		
	Estimate	95% CI	
• Distal to 2nd premolar	8.97	7.64	10.30
• at apex of 2nd premolar	7.51	6.61	8.41
• between 1st & 2nd premolars	6.20	5.33	7.07
• at apex of 1st premolar	6.35	4.54	8.15
Distance to 2nd premolar			
• Distal to 2nd premolar	4.33	3.27	5.39
• at apex of 2nd premolar	4.55	3.84	5.27
• between 1st & 2nd premolars	6.11	5.42	6.81
• at apex of 1st premolar	6.30	4.78	7.82

The relationship between distances to the 1st and 2nd premolars and the position of the foramen is shown in Figure 7.

Fig. 7: Relationship between Distance from Apices of 1st and 2nd Premolar to Foramen and Horizontal and Vertical Position of the Foramen

(X axis: Average Distance in Millimeters for a Foramen that is Positioned Between and Apical to both Premolars, Y axis: Position) (d = distal to 2nd premolar, b/t = between 1st and 2nd premolars, 2 = at 2nd premolar, A = apical to apex, C = coronal to apex)

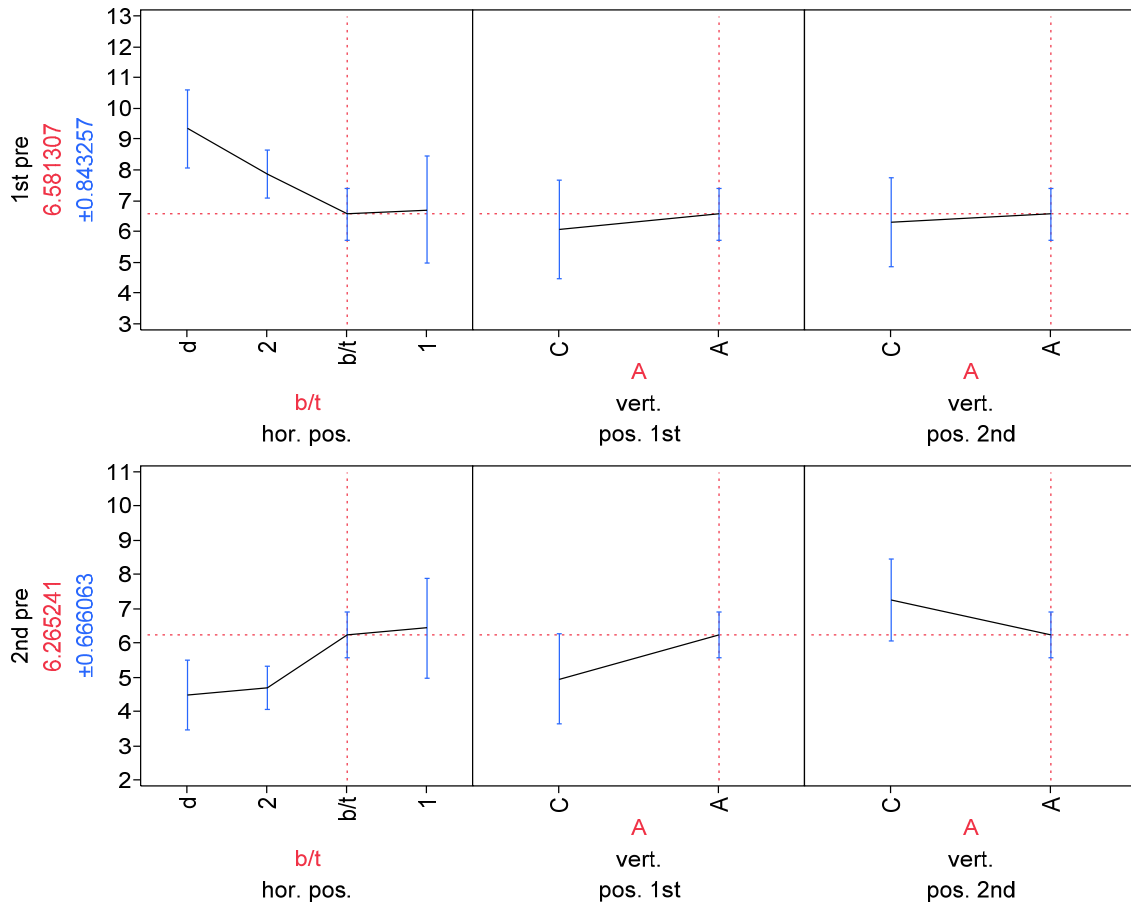


Table 5 illustrates that correlations were noticed between the distance measurements between right and left side. Based on correlation analysis, the distance from the right 1st premolar to the foramen can be used as a reasonable predictor for the distance from the left 1st premolar to the foramen. The same can be said for the 2nd premolars and the distance from both premolars to the inferior border of the mandible. Correlation values approaching 1.00 indicate a higher incidence of predictability.

Table 5: Correlation of Left Sided Measurements and Right Sided Measurements
(Correlations are Highlighted)

	1st left premolar	1st right premolar	2nd left premolar	2nd right premolar	left inferior border	right inferior border
1st left premolar	1	0.5998	0.0157	-0.1888	-0.2829	-0.1581
1st right premolar	0.5998	1	-0.0755	-0.3472	0.0841	0.1098
2nd left premolar	0.0157	-0.0755	1	0.5717	-0.036	-0.1204
2nd right premolar	-0.1888	-0.3472	0.5717	1	-0.2305	-0.2839
left inferior border	-0.2829	0.0841	-0.036	-0.2305	1	0.6898
right inferior border	-0.1581	0.1098	-0.1204	-0.2839	0.6898	1

Conclusion

For years researchers have been trying to determine the location of the mental foramen by using conventional periapical and panoramic radiographs. The use of these modalities only allows the practitioner the ability to adequately determine the foramen's location in 46.8-75% of the time (6,12). Due to the varying reliability of these types of radiographs, research has varied greatly regarding the anatomy of the mental foramen (3,5-9,11,12,14-16).

The use of CBCT has proven itself to be a highly accurate tool for measuring in three dimensions. CBCT has been shown to have an error of less than 0.6% especially when measuring mandibular anatomy (29). Application of such an accurate technology has allowed this research to elucidate the relative positions of mental foramina. Of the 29 patients assessed by CBCT analysis the average distance of mental foramen from mandibular 1st premolar was 7.43mm (SD=1.97), from mandibular 2nd premolar was 5.30mm (SD=1.65), and from inferior border of foramina to the inferior border of the mandible was 11.44mm (SD=1.49). The realization that the foramen may exist as little as 3.65mm from a root apex is especially concerning since many studies have shown periapical lesions and osteotomies as large as 10mm in diameter (32,33). This fact may alter the way practitioners treatment plan surgeries.

Upon examination of the horizontal and vertical positions of the mental foramen, the foramen was located at the 2nd premolar in 41% of cases and between the 1st and 2nd premolars in 38% of cases. Previous studies have shown the foramen to be at the 2nd premolar in a greater percentage of cases. These studies found the foramen in line with the 2nd premolar in 42- 62.7% of cases (5,10,11). Only one past study had a 41% incidence of the foramen between the 1st and 2nd premolars (13). The current study also differed from past studies in the vertical location of the mental foramen. Eighty-three percent of mental foramina were found apical to the apices of the 1st and 2nd premolars. This finding differs greatly from the findings of previous researcher which found the foramen to be coronal to the apex of 1st premolars 38.6% of the time, at the apex 15.4% of the time, and apical to the apex 46.0%; coronal to the apex of 2nd premolars 24.5% of the time, at the apex 13.9% of the time, and apical to the apex 61.6% of the time (12).

The study also illustrates that sex and age can have some significance on the position of the foramen. These trends are particularly clear for the location of the foramen in relationship to the inferior border of the mandible and in the foramen's horizontal position. The foramen is distinctly farther away from the inferior border in male patients and older patients. An increase averaging 0.0885mm per year of patients' age is seen. Based on the significant differences between sexes regarding the distance of foramina to the inferior border of the mandible, the measurement may be useful in identifying the sex of human mandibles in the field of forensics.

There is a tendency for greater distal positioning of the foramen in female patients and in older patients. Additionally, the foramina of older patients have a trend toward

greater apical positioning in relation to the mandibular 1st premolar.

Considering the increased distal and apical positioning of the mental foramen seen to occur as age increases one would hypothesize that the foramen must move as people age. The prevailing thought from numerous growth studies over the last century was that facial skeletal growth stopped soon after puberty (34). However, recent studies have shown continued facial skeletal growth through adulthood (34-37). As we age (range = 25 to 83), the overall length of the mandible, as well as the body and ramus, increases. Males have more of a downward and forward movement, while females move straight down (35). The height of the mandible increases 2.5 ± 2.0 mm through adulthood, with new bone deposited at the inferior border (37). Addition of this bone throughout adulthood explains the greater distance between the mental foramen and the inferior border of the mandible as patients age. The increase in the height of the mandible may also explain the greater apical position of the foramen as the foramen moves with the bone while the teeth stay relatively constant with the unchanged mandibular plane (37). To determine if the foramen moves with age in any one person longitudinal studies would need to be undertaken.

Lastly, the distalization of the foramen relative to the apices of the 1st premolar may be a consequence of the constant mesial migration of teeth. Cephalometric tracings from early adulthood throughout life show a distinct mesial migration of teeth (34,37). Another study showed even patients with congenitally missing 3rd molars exhibit distinct mesial crowding over time due to mesial migration (36).

These results and their comparisons to existing research illustrate that the position of the mental foramen is not a fixed and predictable location. It is also clear that age and gender can have an effect on the location of the foramen. Since the foramen does not have any static and dependable landmarks it is a practitioner's responsibility to gain an understanding of the mental foramen's location with adequate imaging prior to initiating surgical intervention, therefore, reducing the risk of surgical sequelae.

References

References

- (1) Montagu MF. The direction and position of the mental foramen in the great apes and man. *Am.J.Phys.Anthropol.* 1954 Dec;12(4):503-518.
- (2) de Freitas V, Madeira MC, Pinto CT, Zorzetto NL. Direction of the mental canal in human mandibles. *Aust.Dent.J.* 1976 Aug;21(4):338-340.
- (3) Yosue T, Brooks SL. The appearance of mental foramina on panoramic radiographs. I. Evaluation of patients. *Oral Surg.Oral Med.Oral Pathol.* 1989 Sep;68(3):360-364.
- (4) Lill W, Solar P, Ulm C, Watzek G, Blahout R, Matejka M. Reproducibility of three-dimensional CT-assisted model production in the maxillofacial area. *Br.J.Oral Maxillofac.Surg.* 1992 Aug;30(4):233-236.
- (5) Neiva RF, Gapski R, Wang HL. Morphometric analysis of implant-related anatomy in Caucasian skulls. *J.Periodontol.* 2004 Aug;75(8):1061-1067.
- (6) Phillips JL, Weller RN, Kulild JC. The mental foramen: 1. Size, orientation, and positional relationship to the mandibular second premolar. *J.Endod.* 1990 May;16(5):221-223.
- (7) Ngeow WC, Yuzawati Y. The location of the mental foramen in a selected Malay population. *J.Oral Sci.* 2003 Sep;45(3):171-175.
- (8) Kekere-Ekun TA. Antero-posterior location of the mental foramen in Nigerians. *Afr.Dent.J.* 1989 Oct;3(2):2-8.
- (9) Wang TM, Shih C, Liu JC, Kuo KJ. A clinical and anatomical study of the location of the mental foramen in adult Chinese mandibles. *Acta Anat.(Basel)* 1986;126(1):29-33.
- (10) Tebo HG. Variations in position of the mental foramen. *Dent.Items Interest* 1951 Jan;73(1):52-53.
- (11) Phillips JL, Weller RN, Kulild JC. The mental foramen: 2. Radiographic position in relation to the mandibular second premolar. *J.Endod.* 1992 Jun;18(6):271-274.

- (12) Fishel D, Buchner A, Hershkowitz A, Kaffe I. Roentgenologic study of the mental foramen. *Oral Surg.Oral Med.Oral Pathol.* 1976 May;41(5):682-686.
- (13) Moiseiwitsch JR. Position of the mental foramen in a North American, white population. *Oral Surg.Oral Med.Oral Pathol.Oral Radiol.Endod.* 1998 Apr;85(4):457-460.
- (14) Phillips JL, Weller RN, Kulild JC. The mental foramen: 3. Size and position on panoramic radiographs. *J.Endod.* 1992 Aug;18(8):383-386.
- (15) Kieser J, Kuzmanovic D, Payne A, Dennison J, Herbison P. Patterns of emergence of the human mental nerve. *Arch.Oral Biol.* 2002 Oct;47(10):743-747.
- (16) Oguz O, Bozkir MG. Evaluation of location of mandibular and mental foramina in dry, young, adult human male, dentulous mandibles. *West Indian Med.J.* 2002 Mar;51(1):14-16.
- (17) Nakajima A, Sameshima GT, Arai Y, Homme Y, Shimizu N, Dougherty HS. Two- and three-dimensional orthodontic imaging using limited cone beam-computed tomography. *Angle Orthod.* 2005 Nov;75(6):895-903.
- (18) Rigolone M, Pasqualini D, Bianchi L, Berutti E, Bianchi SD. Vestibular surgical access to the palatine root of the superior first molar: "low-dose cone-beam" CT analysis of the pathway and its anatomic variations. *J.Endod.* 2003 Nov;29(11):773-775.
- (19) Laster WS, Ludlow JB, Bailey LJ, Hershey HG. Accuracy of measurements of mandibular anatomy and prediction of asymmetry in panoramic radiographic images. *Dentomaxillofac.Radiol.* 2005 Nov;34(6):343-349.
- (20) Tronje G, Eliasson S, Julin P, Welander U. Image distortion in rotational panoramic radiography. II. Vertical distances. *Acta Radiol.Diagn.(Stockh)* 1981;22(4):449-455.
- (21) Habets LL, Bezuur JN, van Ooij CP, Hansson TL. The orthopantomogram, an aid in diagnosis of temporomandibular joint problems. I. The factor of vertical magnification. *J.Oral Rehabil.* 1987 Sep;14(5):475-480.
- (22) Kjellberg H, Ekestubbe A, Kiliaridis S, Thilander B. Condylar height on panoramic radiographs. A methodologic study with a clinical application. *Acta Odontol.Scand.* 1994 Feb;52(1):43-50.

- (23) Turp JC, Vach W, Harbich K, Alt KW, Strub JR. Determining mandibular condyle and ramus height with the help of an Orthopantomogram--a valid method? *J.Oral Rehabil.* 1996 Jun;23(6):395-400.
- (24) Xie Q, Soikkonen K, Wolf J, Mattila K, Gong M, Ainamo A. Effect of head positioning in panoramic radiography on vertical measurements: an in vitro study. *Dentomaxillofac.Radiol.* 1996 Apr;25(2):61-66.
- (25) Catic A, Celebic A, Valentic-Peruzovic M, Catovic A, Jerolimov V, Muretic I. Evaluation of the precision of dimensional measurements of the mandible on panoramic radiographs. *Oral Surg.Oral Med.Oral Pathol.Oral Radiol.Endod.* 1998 Aug;86(2):242-248.
- (26) Mckee IW, Glover KE, Williamson PC, Lam EW, Heo G, Major PW. The effect of vertical and horizontal head positioning in panoramic radiography on mesiodistal tooth angulations. *Angle Orthod.* 2001 Dec;71(6):442-451.
- (27) Stramotas S, Geenty JP, Petocz P, Darendeliler MA. Accuracy of linear and angular measurements on panoramic radiographs taken at various positions in vitro. *Eur.J.Orthod.* 2002 Feb;24(1):43-52.
- (28) White SC. Cone-beam imaging in dentistry. *Health Phys.* 2008 Nov;95(5):628-637.
- (29) Ludlow JB, Laster WS, See M, Bailey LJ, Hershey HG. Accuracy of measurements of mandibular anatomy in cone beam computed tomography images. *Oral Surg.Oral Med.Oral Pathol.Oral Radiol.Endod.* 2007 Apr;103(4):534-542.
- (30) Pinsky HM, Dyda S, Pinsky RW, Misch KA, Sarment DP. Accuracy of three-dimensional measurements using cone-beam CT. *Dentomaxillofac.Radiol.* 2006 Nov;35(6):410-416.
- (31) Moiseiwitsch JR. Avoiding the mental foramen during periapical surgery. *J.Endod.* 1995 Jun;21(6):340-342.
- (32) Pecora G, Kim S, Celletti R, Davarpanah M. The guided tissue regeneration principle in endodontic surgery: one-year postoperative results of large periapical lesions. *Int.Endod.J.* 1995 Jan;28(1):41-46.
- (33) von Arx T, Cochran DL. Rationale for the application of the GTR principle using a barrier membrane in endodontic surgery: a proposal of classification and literature review. *Int.J.Periodontics Restorative Dent.* 2001 Apr;21(2):127-139.

- (34) Pecora NG, Baccetti T, McNamara JA,Jr. The aging craniofacial complex: a longitudinal cephalometric study from late adolescence to late adulthood. Am.J.Orthod.Dentofacial Orthop. 2008 Oct;134(4):496-505.
- (35) Behrents RG. The biological basis for understanding craniofacial growth during adulthood. Prog.Clin.Biol.Res. 1985;187:307-319.
- (36) Thilander B. Dentoalveolar development in subjects with normal occlusion. A longitudinal study between the ages of 5 and 31 years. Eur.J.Orthod. 2009 Apr;31(2):109-120.
- (37) West KS, McNamara JA,Jr. Changes in the craniofacial complex from adolescence to midadulthood: a cephalometric study. Am.J.Orthod.Dentofacial Orthop. 1999 May;115(5):521-532.

Vita

Sanjay Bhagchandani was born on September 21st, 1976 in Richmond, VA. He is currently a citizen of the United States of America. Dr. Bhagchandani received a Bachelor of Science in Biology from Duke University in 1998 followed by a Doctor of Medical Dentistry from Tufts University School of Dental Medicine in 2003. Dr. Bhagchandani practiced general dentistry for five years prior to enrolling in the Advanced Specialty Program in Endodontics at Virginia Commonwealth University School of Dentistry. Dr. Bhagchandani is a member of the AAE, ADA, VDA, Richmond Dental Society, Apollonia Study Club and Richmond Inter-disciplinary Study Club. Dr. Bhagchandani will enter private practice in Richmond, VA with his wife, Dr. Trisha Krause, upon graduation. He will graduate from VCU with an Master of Science in Dentistry and a Certificate in Endodontics.